


CASE REPORT

Open Access



Peripheral vascular disease – a new vascular disease associated with normal tension glaucoma: a case report

Ali Nowrouzi^{*} , Javier Benitez-del-Castillo, Sepideh Kafi-abasabadi, Mario Rodriguez-Calzadilla, Antonio Diaz-Ramos, Alejo Rodriguez-Suarez and Inmaculada Mota-Chozas

Abstract

Introduction: Normal-tension glaucoma is known as a multifactorial optic neuropathy. A number of lines of evidence suggested that vascular factors played a significant role in the development of normal-tension glaucoma. The mechanisms underlying the abnormal ocular blood flow in normal-tension glaucoma are still not clear. Peripheral vascular disease seems to be associated with glaucoma populations independent of other cardiovascular risk factors. We found this presentation, for the first time, to our knowledge, as another probable vascular abnormality related to our patient with normal-tension glaucoma, although it is necessary to confirm its pathological effect in future studies.

Case presentation: Our patient was a 48-year-old Spanish man without any personal and family history of interest except for circulatory problems of the lower limbs with repetitive ulcers at the frontal and lateral aspects of his legs. His chief complaint was vision loss when he came to consult us. In exploration, his best corrected visual acuity was 20/20 in both eyes; initial intraocular pressure in the right eye was 14–16 mmHg and in the left eye was 16–18 mmHg, with a mild sclerosis of the lens in slit-lamp examination. No inflammation or pigmented lesion was detected in the anterior chamber. Open angle confirmed by Goldman four quadrants gonioscopy. Funduscopy examination revealed a vertical cup disc ratio of 0.6 in the right eye and 0.8 in the left eye. The patient's neuroretinal rim was normal in the right eye, and superior thinning in the left eye was determined. Examination of the patient's visual field showed inferior mild probable nasal scotoma in the right eye and an inferior deep arcuate scotoma defect in the left eye. His optical coherence tomography examination revealed thinning of the peripapillary nerve fiber layer thickness in the left eye and superior loss of macular retinal ganglion cells in the left eye. Normal intraocular pressure values were measured on the intraocular pressure curve without treatment (maximum value, 18–20 mmHg), discarding higher intraocular pressures measured out of office. Ultrasonic pachymetry measured 515/520 μm , and normal intraocular pressure measured with a PASCAL tonometer ruled out probable corneal biomechanical underestimations. The patient's polysomnography study was normal and excluded sleep apnea syndrome. The patient's serial mean blood pressure was normal, especially in the lower limbs (mean value, 125/70 mmHg), ruling out the possibility of systemic hypotension. Thyroidal and coagulation abnormalities, autoimmune disease, and inflammatory disease were excluded. Normal immunologic study and normal vascular
(Continued on next page)

* Correspondence: alinoroozi_co@yahoo.com

Hospital Jerez de la Frontera, Ronda de Circunvalación, Jerez de la Frontera, 11407 Cádiz, Spain



© The Author(s). 2020 **Open Access** This article is licensed under a Creative Commons Attribution 4.0 International License, which permits use, sharing, adaptation, distribution and reproduction in any medium or format, as long as you give appropriate credit to the original author(s) and the source, provide a link to the Creative Commons licence, and indicate if changes were made. The images or other third party material in this article are included in the article's Creative Commons licence, unless indicated otherwise in a credit line to the material. If material is not included in the article's Creative Commons licence and your intended use is not permitted by statutory regulation or exceeds the permitted use, you will need to obtain permission directly from the copyright holder. To view a copy of this licence, visit <http://creativecommons.org/licenses/by/4.0/>. The Creative Commons Public Domain Dedication waiver (<http://creativecommons.org/publicdomain/zero/1.0/>) applies to the data made available in this article, unless otherwise stated in a credit line to the data.

(Continued from previous page)

biopsy were observed, as well as normal brain magnetic resonance imaging and a normal carotid vascular study. The primary diagnosis was moderate medium peripheral arterial disease in the lower limbs, which was confirmed by echography after ruling out other probable vascular abnormalities related to normal-tension glaucoma.

Conclusion: After ruling out other systemic diseases and vascular abnormalities related to normal-tension glaucoma, we found peripheral arterial disease as a probable vascular abnormality related to normal-tension glaucoma in our patient. To our knowledge, this is the first time such a case has been reported. Thus, further research is needed to determine the relevance of these results to the general population.

Keywords: Normal-tension glaucoma (NTG), Peripheral arterial disease (PAD), Glaucomatous optic neuropathy, Case report

Introduction

Normal-tension glaucoma (NTG) is known as a multifactorial optic neuropathy characterized by progressive retinal ganglion cell (RGC) death and glaucomatous visual field loss. Despite the fact that the intraocular pressure (IOP) in patients with NTG is within the normal range, the glaucomatous optic neuropathy may keep getting worse progressively and irreversibly. A significant percentage of patients with NTG (as high as 21%) have a family history of glaucoma and genetic predisposition to the disease. The disturbed ocular blood flow is a significant factor in the pathogenesis of NTG. The vascular failure, including vasospasms, small-vessel disease, or autoregulatory dysfunction, will lead to perfusion deficits of the optic nerve head (ONH) and retina and furthermore develop into glaucomatous optic neuropathy [1]. Previous studies showed that the impaired systemic and ocular vascular autoregulation was more pronounced in NTG than in high-tension glaucoma, especially in patients with NTG with progressive optic neuropathy, than in those with relatively stable status [2, 3]. Therefore, the ocular blood flow deficit may play an important role in the glaucomatous optic neuropathy in NTG.

Systemic vascular diseases, including migraine, systemic low blood pressure (BP), Alzheimer disease, primary vascular dysregulation (PVD), and Flammer syndrome, are associated with the progression of NTG [4]. It is generally accepted that the risk factors for NTG include patient sex [5, 6], patient race (more frequently seen in Asian than in European or American patients) [7], PVD [8], and low BP [9, 10]. Female patients appeared to be more susceptible to vasospasm and progression of visual field loss in NTG [11]. Similarly, vasospasm was more commonly observed in Asian than in European and American patients, and, correspondingly, NTG was more commonly seen in Asian countries than in most other countries [12, 13]. Migraine, a disorder associated with NTG, is characterized as a vasospastic disorder and is commonly seen in women [14].

Peripheral arterial disease (PAD) is a prevalent vascular abnormality. Claudication represents an early yet

common manifestation of PAD. A clinical history and physical examination combined with an ankle-brachial index can help make a diagnosis of claudication.

Patients at risk for developing PAD are those who are older than 65 years of age, those with risk factors for atherosclerosis (for example, diabetes mellitus, history of smoking, hyperlipidemia, and hypertension), family history of PAD, and having known atherosclerotic disease in another vascular bed (for example, coronary, carotid). Invasive (angiography) and noninvasive (duplex ultrasound, computed tomographic angiography, or magnetic resonance angiography) anatomic testing of the lower extremities is useful to diagnose anatomic location and severity of stenosis for patients with symptomatic PAD [15, 16].

Case presentation

Our patient was a 48-year-old man without any history of interest (nonsmoker and without any dyslipidemia) without any significant medication history except circulatory problems of the lower limbs and without any relevant family history. His chief complaint was vision loss when he came to consult our institution. Exploration revealed that his best corrected visual acuity was 20/20 in both eyes. His initial IOP without treatment in the right eye was 14–16 mmHg, and his initial IOP in his left eye was 16–18 mmHg. Slit-lamp exploration revealed mild sclerosis of the lens, and in Goldman gonioscopy, an open angle was confirmed in four quadrants (Shaffer scale grade 4). No inflammation was observed in the anterior chamber. No pigmented dispersion was detected on the corneal surface or lens or angle. In fundoscopic examination, the patient's vertical cup disc ratio was 0.6 in the right eye and 0.8 in the left eye. His neuroretinal rim was normal in the right eye, and superior thinning in the left eye was detected without any optic disc drusen. In the patient's visual field, inferior mild probable nasal scotoma was observed in the right eye and an inferior deep arcuate scotoma defect was seen in the left eye (Fig. 1). Optical coherence tomography (OCT) revealed thinning of the peripapillary nerve fiber layer

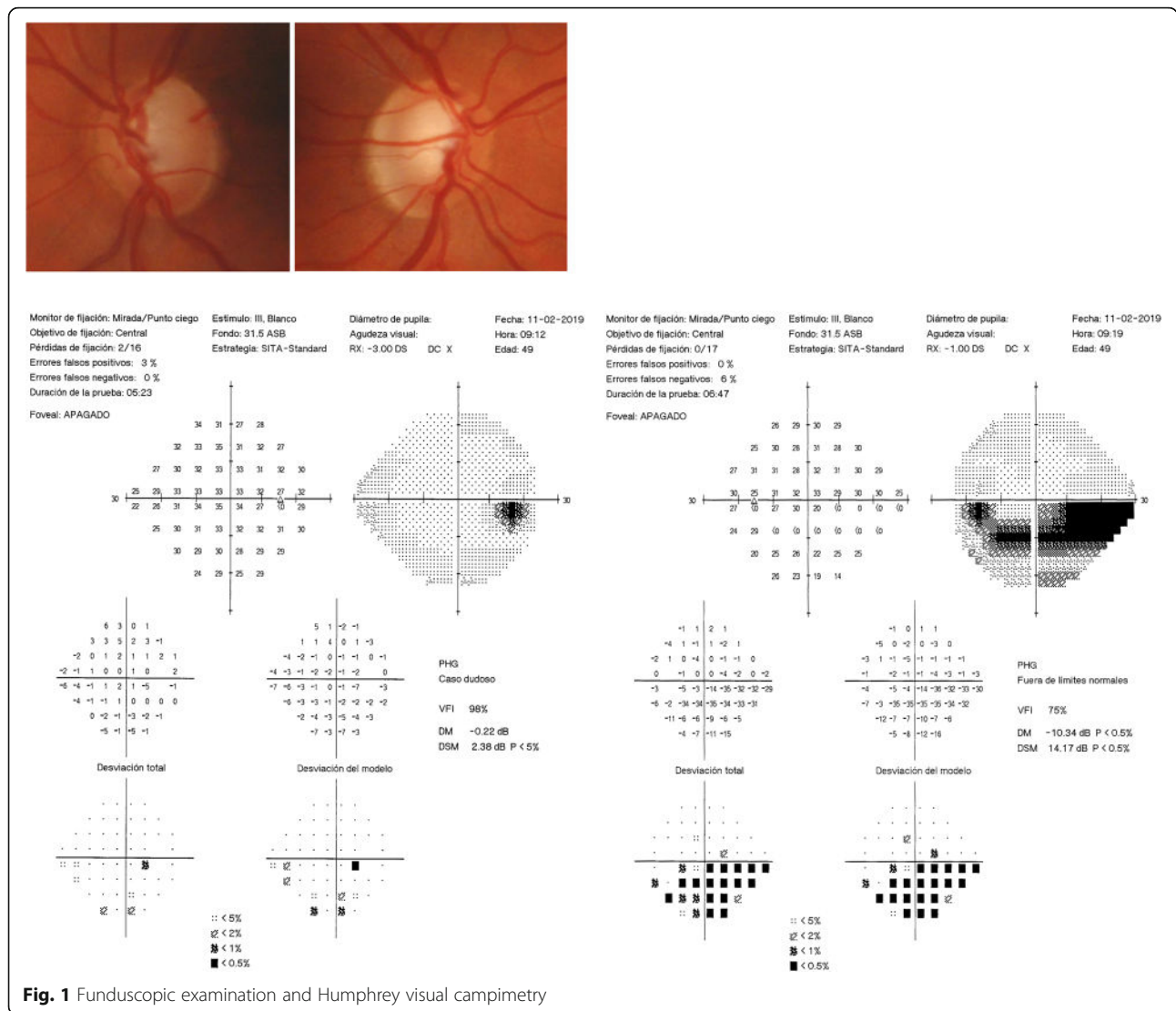


Fig. 1 Funduscopy examination and Humphrey visual campimetry

thickness in the left eye and superior loss of the macular RGC in the left eye (acceptable quality of images, right eye, 58; left eye, 48) (Fig. 2).

Normal IOP values were found in the patient’s diurnal IOP curve without treatment (maximum value, 18–20 mmHg), discarding higher IOPs measured out of office (Fig. 3). The patient’s ultrasound pachymetry measurement was 515/520 μm , and he had normal IOP measured with a PASCAL tonometer (no corneal biomechanical underestimation). The result of his polysomnography (Fig. 4) study was normal, excluding sleep apnea syndrome (SAS).

The patient had normal IOP values in his diurnal IOP curve without treatment (maximum value, 18–20 mmHg), discarding higher IOPs measured out of office. The finding of ultrasound pachymetry was 515/520 μm , and the patient had normal IOP measured with a PASCAL tonometer, ruling out probable corneal biomechanical underestimations. The patient had a normal polysomnography

study, excluding SAS, and normal macular and peripapillary angio-OCT findings were detected.

The patient’s serial mean BP, especially in the lower limbs (mean value, 125/70 mmHg), ruled out the possibility of systemic hypotension. Thyroid and coagulation abnormalities and autoimmune disease and inflammatory disease were excluded by normal thyroid-stimulating hormone (TSH), T4, prothrombin time (PT), partial thromboplastin time (PTT), bleeding time (BT), and negative anticardiolipin antibody, as well as other immunologic study and normal vascular biopsy. The findings of the patient’s brain magnetic resonance imaging (MRI) were normal, as was his carotid vascular study.

Primary diagnosis

Moderate medium PAD in the lower limbs was confirmed by echography on the basis of suprapopliteal arterial stenosis (increased systolic rise time and loss of pulsatility).

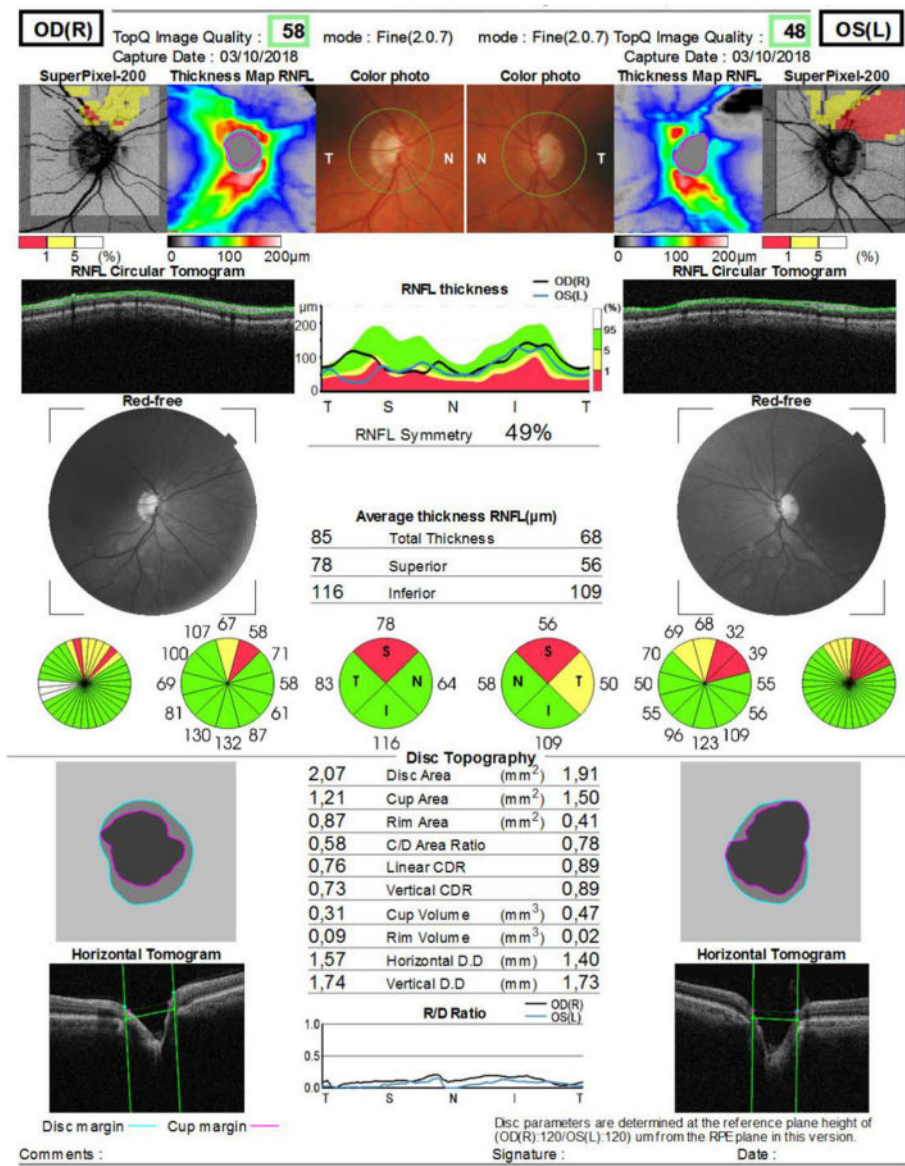


Fig. 2 Optical coherence tomography of optic nerves

Bilateral lesions were observed in his physical examination, and decreased pulses and some bruits were detected, especially in the left leg, without any resting ankle-brachial index (ABI) abnormalities. His lower BP level of 120/70 mmHg was normal.

Discussion

A main cause of the disturbed autoregulation of ocular blood flow was the PVD syndrome frequently observed in patients with NTG [6]. The retinal vessels of patients with PVD usually show a higher spatial irregularity and higher stiffness [17, 18], which was not observed in our patient. PVD was known to be a main cause of splinter hemorrhages at the border of the ONH, which may explain why ONH hemorrhages often

occur in patients with NTG [19, 20]. In terms of circulation, patients with PVD have an inborn tendency to respond differently to various stimuli, such as cold [21]. Vasoconstriction was the most apparent pathological reaction [6]. In addition, ocular blood flow was correlated with peripheral circulation in patients with PVD, such as in their fingers [22]. A repeated but very mild ocular blood flow decrease, mainly due to disturbed autoregulation and ocular perfusion pressure fluctuation, would lead to an unstable oxygen supply and increased local mitochondrial oxidative stress [23–26]. This process was a recognized pathophysiological mechanism of glaucomatous optic neuropathy. In our patient’s case, we could not detect any related symptomatic PVD, such as finger symptoms, related to cold.

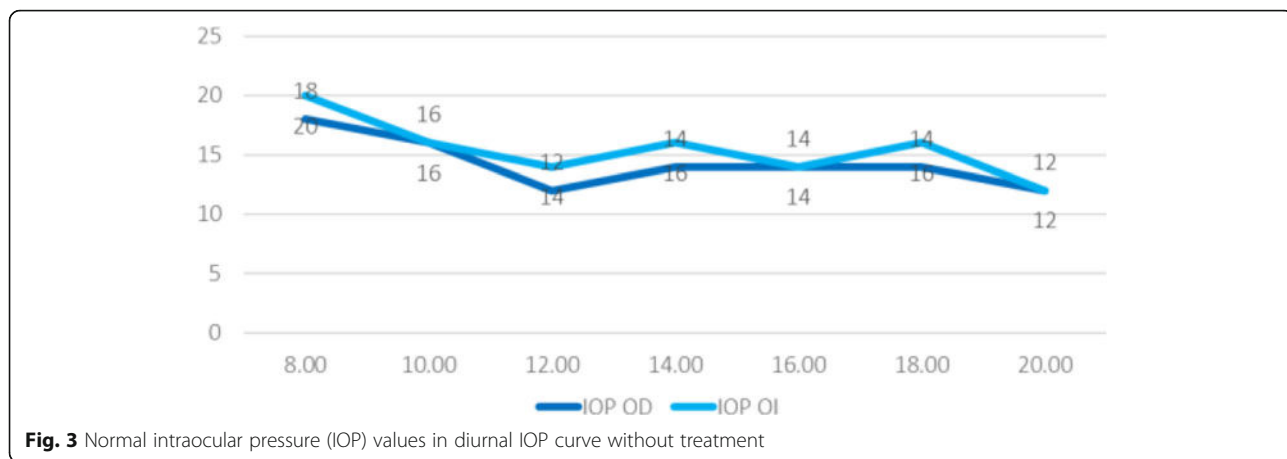


Fig. 3 Normal intraocular pressure (IOP) values in diurnal IOP curve without treatment

Vasospasm

Vasospasm may play a key role in ONH damage and may lead to systemic autoregulatory dysfunction in patients with NTG. Previous studies showed that vasospasm created an environmental dysregulation of blood flow, which increased the vulnerability of the ONH to vascular challenges, and this caused perfusion instability, ischemic changes, reperfusion injury, and axonal loss of the ONH [27, 28]. Vasospasm was common and associated with multiple diseases. However, it appeared to be a transient phenomenon that

could be reversible by improving retrobulbar hemodynamics in patients with NTG using calcium channel blockers [6]. Although vasospasm is a pathological feature in NTG, we did not observe any related symptoms, which could confirm the pathological cause of vasospasm in our patient’s case.

Endothelial dysfunction

Previous studies showed that the vascular endothelium regulated the microcirculation through release of vasoactive

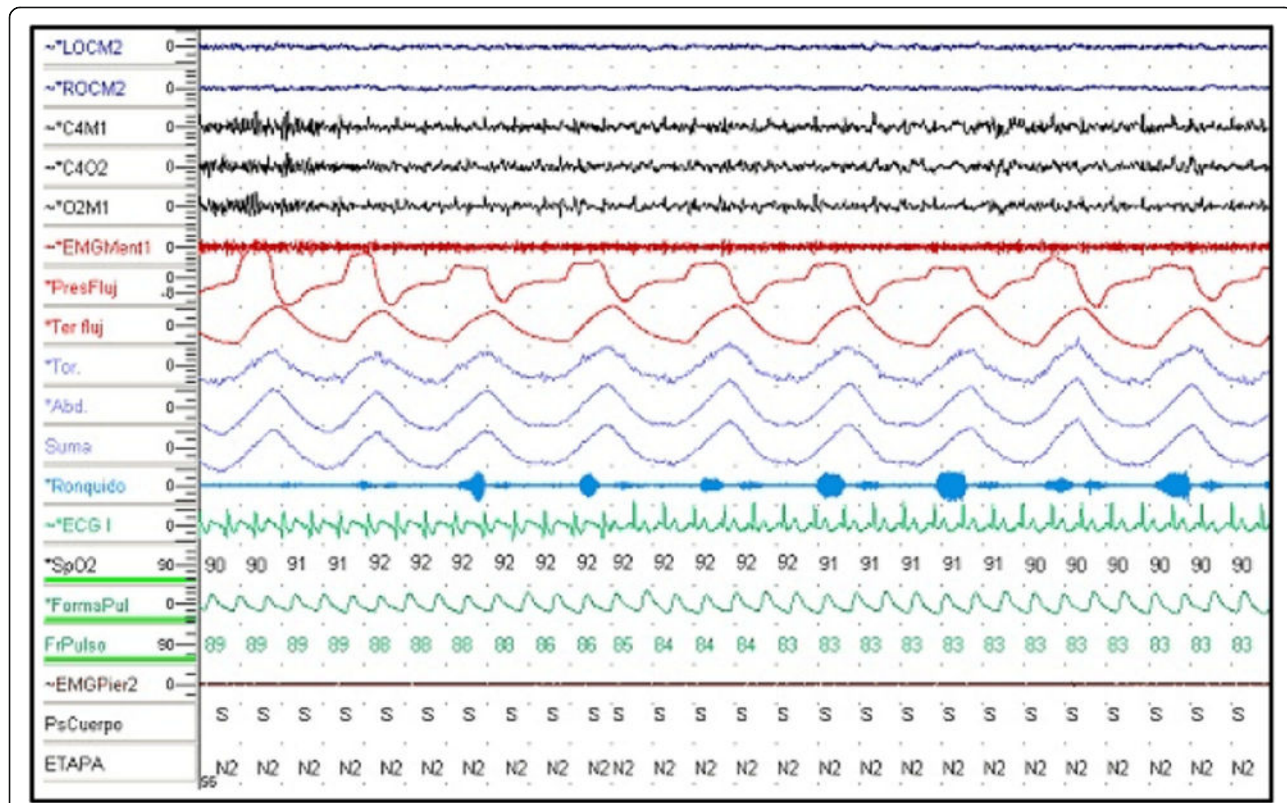


Fig. 4 Polysomnography

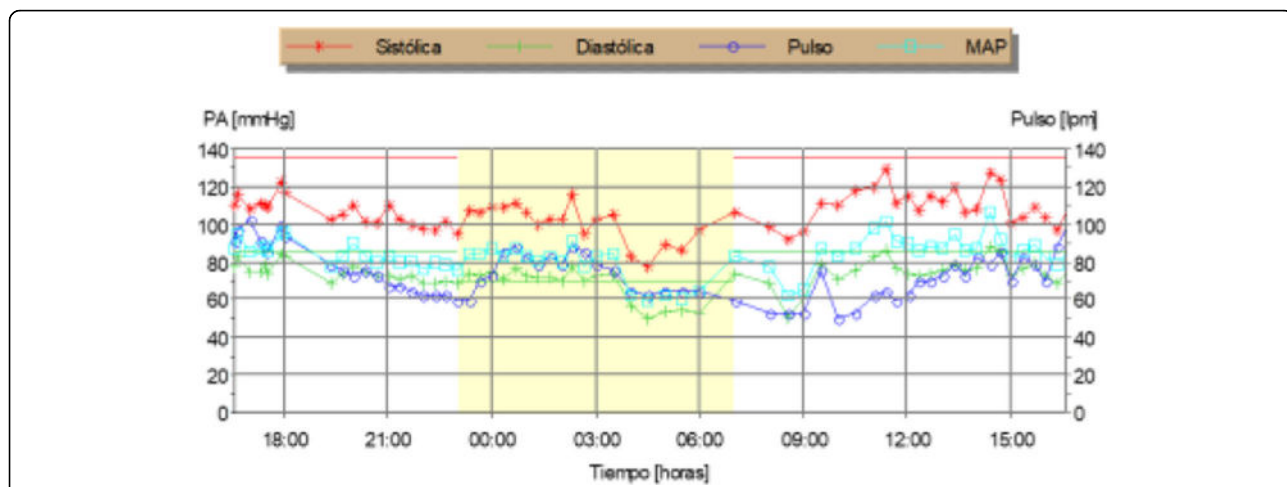


Fig. 5 Normal serial blood pressure (BP) during a cycle of 24 hours mean arterial pressure monitoring. Red dots = systolic BP; green dots = diastolic BP; purple dots = pulse; blue dots = mean arterial pressure

factors, including the vasodilator nitric oxide (NO) and the vasoconstrictor endothelin-1 (ET-1) [29]. NO released from endothelial cells directly stimulated the surrounding vascular smooth muscle to promote vasodilation [30]. Systemic factors such as hyperlipidemia, atherosclerosis, and hyperglycemia impaired endothelial NO signaling through oxidative stress damage [31]. It was known that NO activity contributed to ocular autoregulation and could protect the endothelium and nerve fiber layer against pathologic stresses implicated in glaucoma [30]. Opposing the vasodilatory properties of NO was ET-1, the most important and potent vascular constricting factor [32]. A number of studies demonstrated the increased plasma ET-1 levels in patients with NTG [33, 34]. *In vitro* and animal studies showed that ET-1 exerted its vasoconstrictor effects mainly on the microvessels in the retina [35], which could reduce the blood supply to the optic nerve [36]. Buckley *et al.*

identified that dysfunction of systemic vascular endothelial cells caused decreased responsiveness to ET-1 stimulation in patients with NTG [37]. Endothelial dysfunction is likely related to NTG, and the endothelial dysfunction may be primary or secondary to vascular diseases, including vasospasm and atherosclerosis, in its contribution to NTG pathology.

Endothelial dysfunction plays a key role in atherosclerotic disease. Several methods have been reported to be useful for evaluating endothelial dysfunction. Igari *et al.* demonstrated that the endothelial function measured by peripheral arterial tonometry significantly correlated with the ABI in patients with PAD, and they investigated endothelial dysfunction in patients with PAD [37]. Because the diagnosis of PAD was confirmed in our patient with NTG, we believe that endothelial dysfunction secondary to PAD could be a probable risk factor for and pathological cause

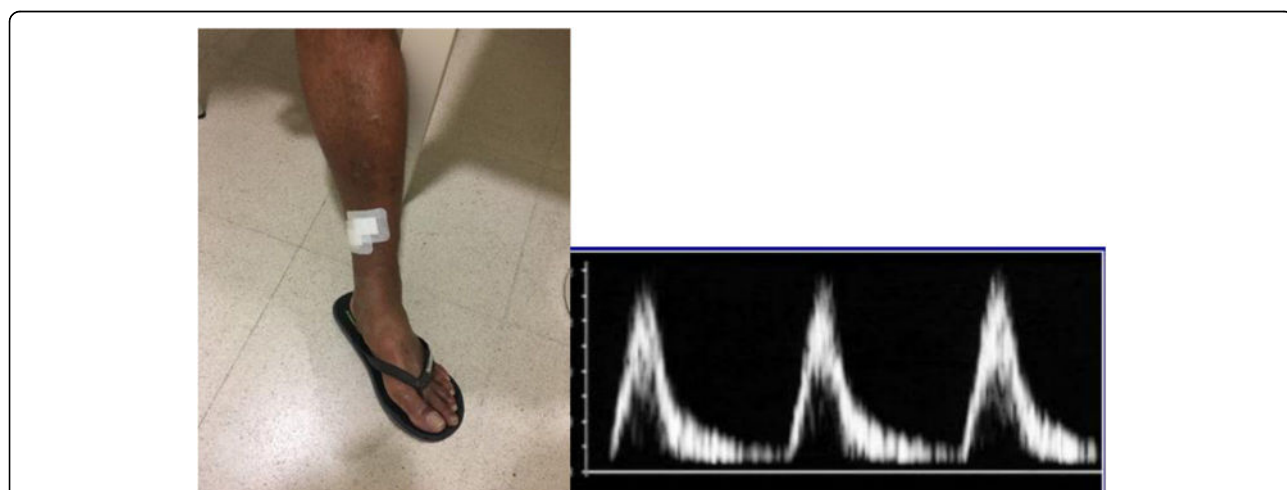


Fig. 6 Echography of lower limbs (suprapopliteal arterial stenosis; increased systolic rise time and loss of pulsatility) and anterior and lateral ulcers of lower limb

of optic nerve damage in our patient's case, although this probable effect should be confirmed in future studies.

After obtaining normal IOP values in diurnal IOP after discarding higher IOPs measured out of office, corneal biomechanical underestimation was excluded by ultrasound pachymetry measuring 515/520 μm and normal IOP measured with a PASCAL tonometer. Our patient's normal polysomnography study finding ruled out SAS as a major risk factor related to NTG.

Our patient's normal serial BP ruled out the possibility of systemic hypotension (Fig. 5). Thyroid and coagulation abnormalities were excluded by normal TSH, T4, PT, PTT, BT, and anticardiolipin antibody. The findings of our patient's brain MRI and carotid vascular study were normal. PAD in the lower limbs was confirmed by echography because of lower limb ulcers (Fig. 6).

An association of PAD with glaucoma has been demonstrated in an Asian population, independent of cardiovascular risk factors. These findings provide further support for the concept that vascular processes and mechanisms that are pressure independent are associated with glaucomatous optic neuropathy [38].

In our patient's case, after ruling out other systemic diseases and vascular abnormalities related to NTG, we found PAD as a probable vascular abnormality related to NTG that causes endothelial dysfunction related to NTG based on Igari *et al.*'s study.

Thus, further research is needed to determine the relevance of these results to the general population, to clarify the temporal nature of the association, and to determine the relationship of PAD with different glaucoma subtypes (primary open-angle glaucoma, primary angle-closure glaucoma, and secondary glaucoma).

Conclusion

Peripheral vascular disease seems to be associated with glaucoma populations independent of other cardiovascular risk factors, which could be associated with NTG, as reported in our patient's case, for the first time, to our knowledge, and should be considered as another vascular abnormality related to NTG.

Abbreviations

ABI: Ankle-brachial index; BP: Blood pressure; BT: Bleeding time; ET-1: Endothelin-1; IOP: Intraocular pressure; MRI: Magnetic resonance imaging; NO: Nitric oxide; NTG: Normal-tension glaucoma; OCT: Optical coherence tomography; ONH: Optic nerve head; PAD: Peripheral arterial disease; PT: Prothrombin time; PTT: Partial thromboplastin time; PVD: Primary vascular dysregulation; RGC: Retinal ganglion cell; SAS: Sleep apnea syndrome; TSH: Thyroid-stimulating hormone

Acknowledgements

We thank Dr. Ariel Juarez for collaborating with us in editing this case presentation.

Authors' contributions

The primer co-author BDC did the interpretation on normotensive glaucoma differential diagnosis and the proper study of the case. SKA helped us to

write the discussion part. MRC and ARS helped us in study of all vascular factors related to normo tensional glaucoma. IMC helped us to study and ruling out other probable systemic disease. All authors attest that they meet the current International Committee of Medical Journal Editors criteria for authorship. The authors read and approved the final manuscript.

Funding

No funding or grant support was received. The authors declare that they have no competing interests and confirm that all relevant data are included in the case presentation.

Ethics approval and consent to participate

This study was conducted in accordance with the fundamental principles of the Declaration of Helsinki.

Consent for publication

Written informed consent was obtained from the patient for publication of this case report and any accompanying images. A copy of the written consent is available for review by the Editor-in-Chief of this journal. Local institutional review board approval was obtained.

Competing interests

The author(s) declare that they have no competing interests and confirm that all relevant data are included in the case presentation. There were not any sources of funding for this case report.

Received: 10 May 2020 Accepted: 14 September 2020

Published online: 19 November 2020

References

- Plange N, Remky A, Arend O. Colour Doppler imaging and fluorescein filling defects of the optic disc in normal tension glaucoma. *Br J Ophthalmol*. 2003;87(6):731–6.
- Kaiser HJ, Schoetzau A, Stumpf D, Flammer J. Blood-flow velocities of the extraocular vessels in patients with high-tension and normal-tension primary open-angle glaucoma. *Am J Ophthalmol*. 1997;123(3):320–7.
- Grunwald JE, Piltz J, Hariprasad SM, DuPont J. Optic nerve and choroidal circulation in glaucoma. *Invest Ophthalmol Vis Sci*. 1998;39(12):2329–36.
- Fan N, Wang P, Tang L, Liu X. Ocular blood flow and normal tension glaucoma. *Biomed Res Int*. 2015;2015:308505.
- Flammer J, Mozaffarieh M. What is the present pathogenetic concept of glaucomatous optic neuropathy? *Surv Ophthalmol*. 2007;52(Suppl 2):S162–73.
- Mozaffarieh M, Flammer J. New insights in the pathogenesis and treatment of normal tension glaucoma. *Curr Opin Pharmacol*. 2013;13(1):43–9.
- Suzuki Y, Iwase A, Araie M, *et al*. Risk factors for open-angle glaucoma in a Japanese population: the Tajimi study. *Ophthalmology*. 2006;113(9):1613–7.
- Konieczka K, Ritch R, Traverso CE, *et al*. Flammer syndrome. *EPMA J*. 2014; 5(1):11.
- Pache M, Dubler B, Flammer J. Peripheral vasospasm and nocturnal blood pressure dipping—two distinct risk factors for glaucomatous damage? *Eur J Ophthalmol*. 2003;13(3):260–5.
- Kim YD, Han SB, Park KH, *et al*. Risk factors associated with optic disc haemorrhage in patients with normal tension glaucoma. *Eye*. 2010;24(4): 567–72.
- Drange S, Anderson DR, Schulzer M. Risk factors for progression of visual field abnormalities in normal-tension glaucoma. *Am J Ophthalmol*. 2001; 131(6):699–708.
- Flammer J, Pache M, Resink T. Vasospasm, its role in the pathogenesis of diseases with particular reference to the eye. *Prog Retin Eye Res*. 2001;20(3): 319–49.
- Beltrame JF, Sasayama S, Maseri A. Racial heterogeneity in coronary artery vasomotor reactivity: differences between Japanese and Caucasian patients. *J Am Coll Cardiol*. 1999;33(6):1442–52.
- Cursiefen C, Wisse M, Cursiefen S, Jünemann A, Martus P, Korth M. Migraine and tension headache in high-pressure and normal-pressure glaucoma. *Am J Ophthalmol*. 2000;129(1):102–4.
- Fowkes FG, Aboyans V, Fowkes FJ, McDermott MM, Sampson UK, Criqui MH. Peripheral artery disease: epidemiology and global perspectives. *Nat Rev Cardiol*. 2017;14(03):156–70.

16. Joosten MM, Pai JK, Bertoia ML, *et al.* Associations between conventional cardiovascular risk factors and risk of peripheral artery disease in men. *JAMA*. 2012;308(16):1660–7.
17. Phelps CD, Corbett JJ. Migraine and low-tension glaucoma: a case-control study. *Invest Ophthalmol Vis Sci*. 1985;26(8):1105–8.
18. Gugleta K, Zawinka C, Rickenbacher I, *et al.* Analysis of retinal vasodilation after flicker light stimulation in relation to vasospastic propensity. *Invest Ophthalmol Vis Sci*. 2006;47(9):4034–41.
19. Kochkorov A, Gugleta K, Zawinka C, Katamay R, Flammer J, Orgul S. Short-term retinal vessel diameter variability in relation to the history of cold extremities. *Invest Ophthalmol Vis Sci*. 2006;47(9):4026–33.
20. Nitta K. Disc hemorrhage is a sign of progression in normal-tension glaucoma. *J Glaucoma*. 2012;21(4):276.
21. Grieshaber MC, Terhorst T, Flammer J. The pathogenesis of optic disc splinter haemorrhages: a new hypothesis. *Acta Ophthalmol Scand*. 2006;84(1):62–8.
22. Hafez AS, Bizzarro R, Descovich D, Lesk MR. Correlation between finger blood flow and changes in optic nerve head blood flow following therapeutic intraocular pressure reduction. *J Glaucoma* 2005;14(6):448–454.
23. Delaney Y, Walshe TE, O'Brien C. Vasospasm in glaucoma: clinical and laboratory aspects. *Optom Vis Sci*. 2006;83(7):406–14.
24. Choi J, Jeong J, Cho HS, Kook MS. Effect of nocturnal blood pressure reduction on circadian fluctuation of mean ocular perfusion pressure: a risk factor for normal tension glaucoma. *Invest Ophthalmol Vis Sci*. 2006;47(3):831–6.
25. Choi J, Kim KH, Jeong J, Cho HS, Lee CH, Kook MS. Circadian fluctuation of mean ocular perfusion pressure is a consistent risk factor for normal-tension glaucoma. *Invest Ophthalmol Vis Sci*. 2007;48(1):104–11.
26. Choi J, Lee JR, Lee Y, *et al.* Relationship between 24-hour mean ocular perfusion pressure fluctuation and rate of paracentral visual field progression in normal-tension glaucoma. *Invest Ophthalmol Vis Sci*. 2013;54(9):6150–7.
27. Moore D, Harris A, Wudunn D, Kheradiya N, Siesky B. Dysfunctional regulation of ocular blood flow: a risk factor for glaucoma? *Clin Ophthalmol*. 2008;2(4):849–61.
28. Schempp H, Elstner EF. Free radicals in the pathogenesis of ocular diseases. In: Haefliger IO, Flammer J, editors. *Nitric oxide and endothelin in the pathogenesis of glaucoma*. Philadelphia: Lippincott-Raven; 1998. p. 112–35.
29. Adams JA. Endothelium and cardiopulmonary resuscitation. *Crit Care Med*. 2006;34(Suppl 12):S458–65.
30. Toda N, Nakanishi-Toda M. Nitric oxide: ocular blood flow, glaucoma, and diabetic retinopathy. *Prog Retin Eye Res*. 2007;26(3):205–38.
31. Napoli C, de Nigris F, Palinski W. Multiple role of reactive oxygen species in the arterial wall. *J Cell Biochem*. 2001;82(4):674–82.
32. Rubanyi GM, Polokoff MA. Endothelins: molecular biology, biochemistry, pharmacology, physiology, and pathophysiology. *Pharmacol Rev*. 1994;46(3):325–415.
33. Lee NY, Park HYL, Park CK, Ahn MD. Analysis of systemic endothelin-1, matrix metalloproteinase-9, macrophage chemoattractant protein-1, and high-sensitivity C-reactive protein in normal-tension glaucoma. *Curr Eye Res*. 2012;37(12):1121–6.
34. Sugiyama T, Moriya S, Oku H, Azuma I. Association of endothelin-1 with normal tension glaucoma: clinical and fundamental studies. *Surv Ophthalmol*. 1995;39(Suppl 1):S49–56.
35. Polak K, Luksch A, Frank B, Jandrasits K, Polska E, Schmetterer L. Regulation of human retinal blood flow by endothelin-1. *Exp Eye Res*. 2003;76(5):633–40.
36. Orgul S, Cioffi GA, Bacon DR, Van Buskirk EM. An endothelin-1 induced model of chronic optic nerve ischemia in rhesus monkeys. *J Glaucoma*. 1996;5(2):135–8.
37. Buckley C, Hadoke PWF, Henry E, O'Brien C. Systemic vascular endothelial cell dysfunction in normal pressure glaucoma. *Br J Ophthalmol*. 2002;86(2):227–32.
38. Jeganathan VS, Wong TY, Foster PJ, *et al.* Peripheral artery disease and glaucoma: the Singapore Malay Eye Study. *Arch Ophthalmol*. 2009;127(7):888–93.

Publisher's Note

Springer Nature remains neutral with regard to jurisdictional claims in published maps and institutional affiliations.

Ready to submit your research? Choose BMC and benefit from:

- fast, convenient online submission
- thorough peer review by experienced researchers in your field
- rapid publication on acceptance
- support for research data, including large and complex data types
- gold Open Access which fosters wider collaboration and increased citations
- maximum visibility for your research: over 100M website views per year

At BMC, research is always in progress.

Learn more biomedcentral.com/submissions

